

TITLE: A CASE REPORT ON A LARGE OVARIAN SEROUS CYSTADENOMA IN POST MENOPAUSAL WOMAN

CASE REPORT

A 55-year-old postmenopausal woman with a history of 2 previous LSCS presented with chief complaint of gradual abdominal distension over the past 2 months.

Clinical Examination

Per Abdominal Examination Revealed a large abdominal mass, corresponding to a 34-week gestational-size uterus.

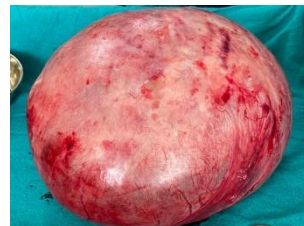
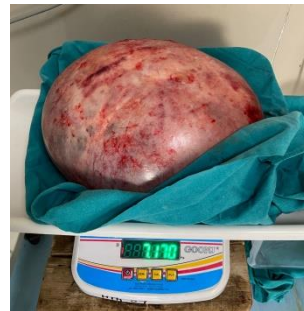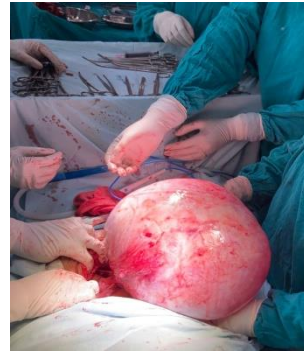Imaging Findings (MRI) revealed a large cystic lesion in the abdominopelvic cavity and multiple internal septations, originating from the right ovary. **Suggestive of a large complex ovarian cyst.**

Surgical Management:

- **Procedure:** Exploratory laparotomy with left ovarian cystectomy, total abdominal hysterectomy, and bilateral salpingo-oophorectomy.
- **Intraoperative Findings:** Large ovarian mass (30 × 25 × 20 cm, 7.1 kg) with a smooth surface and solid-cystic components. Uterus was dextro-rotated, and the mass was located between the two layers of the broad ligament with bowel adhesion.

Histopathology showed cystic structures lined by flattened cuboidal to columnar epithelium with cystic wall composed of edematous fibrocollagenous tissue and congestion. **Features suggestive of benign serous cystadenoma.**

The postoperative course of patient was uneventful.



DISCUSSION & CONCLUSION

- **Ovarian epithelial tumors** comprise about half of all ovarian tumors, accounting for about 40% of benign tumors. Benign serous tumors are common, accounting for about 25% of all benign ovarian neoplasms.
- In postmenopausal women, the risk of malignancy in ovarian tumors increases, requiring **comprehensive evaluation and timely management.**
- **Early diagnosis and histopathological confirmation are key to differentiating benign from malignant lesions.**
- **This is one of the largest benign serous cystadenoma reported in our institute.** The anatomy was distorted as uterus was dextrorotated due to bulk of the tumour.

REFERENCES

- Sujatha VV et al.** Giant ovarian serous cystadenoma in a postmenopausal woman: a case report. Cases J. 2009 Jul 23;2:7875.
- Mülayim B et al.** Unaware of a giant serous cyst adenoma: a case report. Arch Gynaecol Obstet. 2006;273(6):381–383.