



AICOG 2025
Mumbai

67th All India Congress of
Obstetrics & Gynaecology

FOGSI celebrates 75 years –
Diamond Jubilee

8-12 January, 2025 | JIO World Convention Centre

- Poster Number: EP 189 Name: Dr Sushil Chawla , Dr Hrishikesh Magdum , Dr Roobina Grewal
- Title: Case report - Post traumatic Vaginal synechiae, Managed with Vaginoscopic adhesiolysis



INTRODUCTION

Post traumatic vaginal stenosis is a rare but serious complications resulting from injury , infection, or iatrogenic causes.

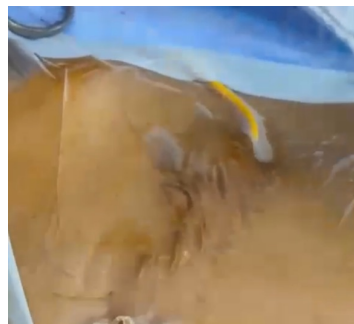It is particularly concerning in adolescents as it can affect their physical health and emotional well being

CASE DESCRIPTION

A 12 year old girl – k/c/o pelvic trauma with left intertrochantric fracture with complete proximal urethral injury at age of 5 years due to road traffic accident

Initially surgical management was done with formation of appendicovesicotomy conduit for draining urine with catheter

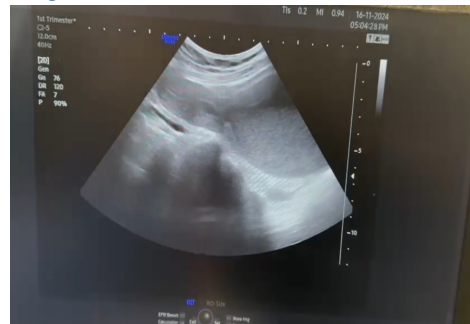FIGURE 1



Examination finding : P/A – Well healed surgical scar with **appendicovesicotomy stoma** to drain the bladder
Perineal examination : Hymen present with no imperforation

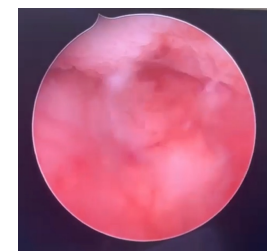
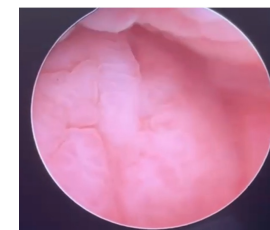
INVESTIGATIONS

Figure 2



Ultrasound – well defined 19 mm x 55mm x 53 mm anechoic area noted distal to cervix (within vagina) measuring 30 cc. Features suggestive of hematocolpos .
MRI –Features suggestive of hydrocolpos likely due to secondary vaginal stenosis at the level of upper 2/3 and lower 1/3 of vagina .

Figure 2 &3



CONCLUSION

Vaginal stenosis caused by trauma is a rare occurrence and proper initial management can prevent it . .

A comprehensive clinical evaluation was performed , including pelvic examinations and imaging studies

Post surgery , the patient exhibited significant improvements in vaginal patency

Psychological assessments indicated a decrease in trauma related symptoms , highlighting the psychological benefits of surgical interventions

REFERENCES

1. Patel S, Patel S , Bhadana P, Shetty R. Post traumatic high vaginal stricture and hematocolpos impersonating vaginal septum in adolescent girl; a case report. Int J Reprod Contracept Obstet Gynecol 2022
2. Kunwar S Khan T , Gupta H. Acquired gynatresia BMJ Case Rep. 2-014;bcr201420359
3. Kaur G Sinha M, Gupta R . Postpartum vaginal stenosis due to chemical vaginitis

MANAGEMENT

SURGICAL INTERVENTIONS –

- EUA with ultrasound guided **vaginoscopy** done
- Vaginoscopy – fibrous band (blind pouch of thick vaginal tissue with no connection to proximal part)
- Ultrasound guided mucus content drained
- Pigtail catheter No 14 Fr inserted over guide wire and fixed

VAGINOSCOPIC ADHESIOLYSIS–

- Vaginal cavity and cervix visualised using pigtail catheter as guide
- Vaginal synechiae on lt lateral wall was cut and released using hysteroscopic scissors

Post operative management –

- Progynova and evalon ointment
- Pigtail catheter in situ