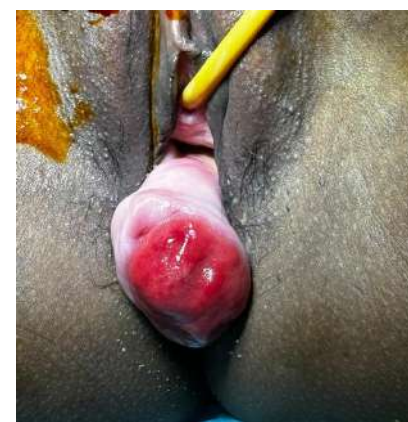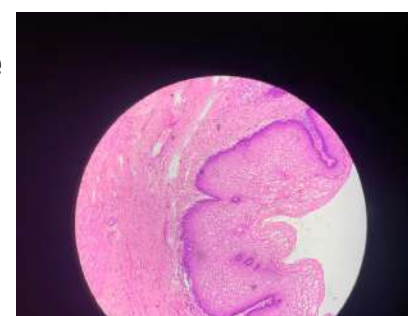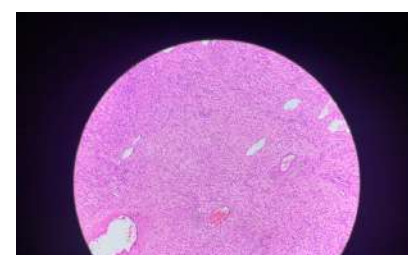


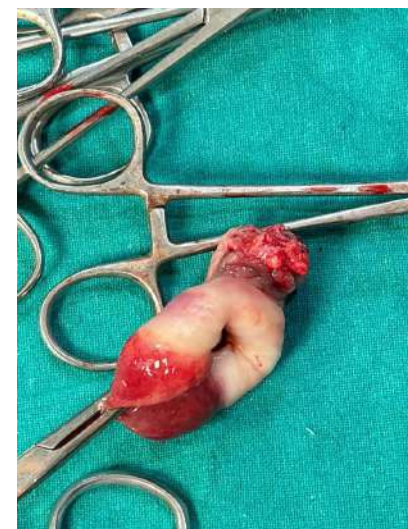Title: **A RARE CELLULAR ANGIOFIBROMA OF VAGINA IN REPRODUCTIVE WOMAN**

INTRODUCTION Angiofibroma is a benign tumour which occurs in genital region in both genders. Occurs more commonly in vulva, rarely seen in vagina. It was first described in 1997 by Nucci et al. This tumour is seen predominantly in vulva of middle age females. It is caused by local overgrowth of collagen, fibroblast and blood vessels, also seen in patients of tuberous sclerosis and MEN 1 syndrome due to genetic mutations. These tumours are mostly asymptomatic, with low risk of metastasis. Few patients may present with secondary infertility, bleeding. The name cellular angiofibroma emphasised the two principal components which are cellular spindle cell and blood vessels. Literature suggests that only 4–5 cases of vaginal angiofibroma have been reported so far.

CASE REPORT

Presenting a case of 24-year-old Para 1 Live 1 with complaint of something coming out of vagina since 4 months and no menstrual complaints. Patient was married for 2 years and last child birth was 9 months ago, uneventful. Patient did not have any history of any urinary or gastrointestinal disturbance. Her general examination within normal limits. On per Abdominal examination – no guarding, rigidity, tenderness. On Gynaecological examination – an approximately 3*2*2 cm firm, nontender growth with thick pedicle and round contour attached to posterior vaginal wall distal from cervix near the introitus which didn't bleed on touch. Cervix and Uterus were normal. Transvaginal ultrasound – suggestive of 3.2*2.5*2.2 cm hypoechoic lesion which shows peripheral vascularity suggestive of vaginal wall fibroma. On per rectal examination – no growth felt per rectally, the rectovaginal wall was felt separate from the mass. Under Spinal Anaesthesia mucosa of the posterior vaginal was incised, mass was enucleated from surrounding tissue. Rectovaginal septum wall was intact. Estimated blood loss was around 50ml. Procedure was uneventful, was tolerated well by patient and was discharged after 2 days. Histopathology report was suggestive of benign spindle cell tumour, possibly angiofibroma of posterior vaginal wall.



DISCUSSION

Cellular Angiofibroma is a well-circumscribed benign stromal tumour, mostly asymptomatic, typically slow-growing non-recurrent. It usually originates from superficial soft tissues of the genital area. Sites that are involved by this tumour are mostly vulva in females and inguinoscrotal area in males, also extragenital organs like knee, eyelid, oral mucosa. This tumour occurs less frequently in vagina. So first this case was misdiagnosed as vaginal wall cyst based on clinical examination and vaginal wall leiomyoma based on ultrasound report. Therefore, pathological examination of surgical specimen can give definitive diagnosis of cellular angiofibroma. On Microscopy, this tumour is composed of spindle stromal cells and abundant blood vessels. Immunohistochemistry may also help in differentiating this tumour from other vulvovaginal soft tissue tumours. Surgery is the only treatment available. Differential diagnosis for this tumour could be Leiomyoma, Angiomyoma, Angiomyofibroblastoma, Squamous cell carcinoma, Adenocarcinoma, Lipoma, rectocele etc.

CONCLUSION

Cellular Angiofibroma is a rare benign soft tissue tumour which is difficult to diagnose before surgery; surgery has been the only treatment method and definitive diagnosis is made by histopathological examination of specimen. Topical rapamycin has been said to be effective in reducing growth of tumour. Cellular angiofibroma rarely occurs in vagina, mostly affects middle-aged women but can also occur in young reproductive-aged women. Long-term follow-up is required for surveillance of recurrence.

